

Oral Respiration: Facial Maldevelopment And Corrective Dentofacial Orthopedics

J. DANIEL SUBTELNY, D.D.S., M.S.

"Normal" respiration is believed to involve adequate utilization of the nasal and the nasopharyngeal tracts. Unusual enlargement of structures within these anatomic areas, such as adenoid tissue within the nasopharynx and nasal turbinates within the nasal cavities, could cause an impediment in the passage of air within the nasorespiratory channel. If the obstruction is of sufficient dimension to preclude nasal respiration, the result may be an adaptation to an oral mode of respiration. As of late, it has come to be realized that an oral mode of respiration, causing postural adaptations of structures in the head and neck region, could have an effect on the positional relationship of the jaws and on the developing occlusion.

In past decades it was not unusual to therapeutically remove enlarged tonsils and adenoid tissue. In more recent years and with justification, there has developed a greater reluctance to perform these procedures. With the latter as a prevailing philosophy, orthodontists have begun to see more problems in dentofacial development seemingly related to the necessity of an oral mode of respiration. Therefore, it would behoove us to examine the nasal and the nasopharyngeal areas, and to evaluate the effects of obstructions in these areas on dentofacial development and, perhaps, to make some suggestions in therapy.

THE NASOPHARYNX:

ADENOID TISSUE AND GROWTH

It seems like a long time ago that

Read at the reunion meeting of the University of Illinois Orthodontic Association, March 1980.

an article entitled, "The Significance of Adenoid Tissue In Orthodontia" appeared in the *Angle Orthodontist* in 1954.¹ At that time, even as today, orthodontists had an enduring interest in the relationship between excessive amounts of adenoid tissue, the developing occlusion, and facial morphology. There had been frequent references to the so-called "adenoid type" face,^{2,3,4} the basic description of a supposedly typical facial configuration due to a superabundance of adenoid tissue inducing mouthbreathing with the concurrent lowering of the mandible and the characteristic parting of the lips. In the 1954 article it was hypothesized that with the dropping of the mandible and the removal of the influence of the lower lip on the maxillary dentition, a greater degree of maxillary dental procumbency could gradually evolve. Comparatively recently, this was shown not to be the end result of the mandibular postural changes incident to large adenoids and mouthbreathing habits. Linder-Aronson⁴ studied, cephalometrically, children selected for an adenoidectomy and compared them with a group of closely comparable control subjects. He found that the youngsters scheduled for an adenoidectomy had longer and narrower faces than the control subjects. Concurrently, he found a retroclination of the upper and lower anterior teeth and a tendency toward an open bite. Thus, it would seem that the co-relation of excessive adenoid tissue and adaptive postures necessitated by mouthbreathing could have an influence on the developing facial structures as well as the dental

occlusion. In the latter instance, it would involve more of a retroclination rather than a proclination of the anterior teeth. Despite the fallacious hypothesis as to the resultant effects of mouthbreathing on the anterior dentition, there was much information forthcoming from the 1954 paper which is pertinent to the present discussion. Initially, it must be acknowledged that adenoid tissue can be visualized on a cephalometric roentgenogram (Fig. 1). It is true that adenoid tissue cannot be radiographically seen as a three-dimensional mass since the lateral cephalometric headplate represents a registration of the midsagittal plane. However, its relative dimension can be readily visualized and analyzed and, more importantly, its positional relationship to contiguous structures can be readily evaluated. Dimensions will vary from individual to individual, but its comparative dimension and position relative to the confines of the nasopharyngeal cavity is what must be carefully evaluated.

The attachment of the adenoid tissue is to the roof of the nasopharynx and may extend as far forward as the posterior nasal choanae. At times it may be seen to apparently obstruct, in a vertical relationship, a major portion of the posterior nasal choanae (Fig. 2). If the encroachment on the posterior nasal choanae is of a significant proportion of that area, then the passage of air from the nasal tract through the nasopharynx may be abnormally reduced or impeded, necessitating oral respiration. Adenoid tissue may also be observed to extend downward from the nasopharyngeal roof approaching the nasal surface of the soft palate to varying degrees. In some instances the inferior surface of the adenoid tissue may be far removed from the soft palate; in others it may closely approach or even approximate

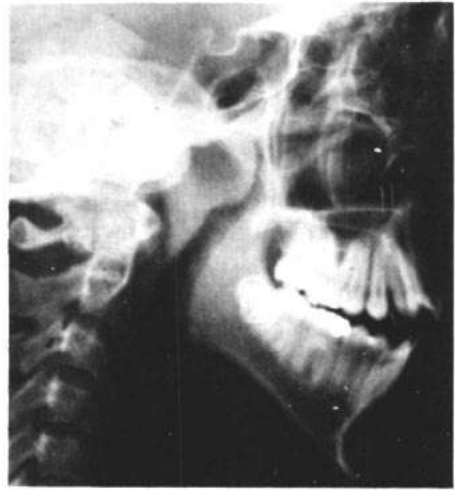


Fig. 1 Lateral cephalometric roentgenogram clearly illustrating the visualization of adenoid tissue in the nasopharyngeal area.

some aspect of the nasal surface of the soft palate. In the latter case there may be an elimination or abnormal reduction in the airway passage through the nasopharynx and mouthbreathing might be the necessary mode of respiration. Thus, an evalu-

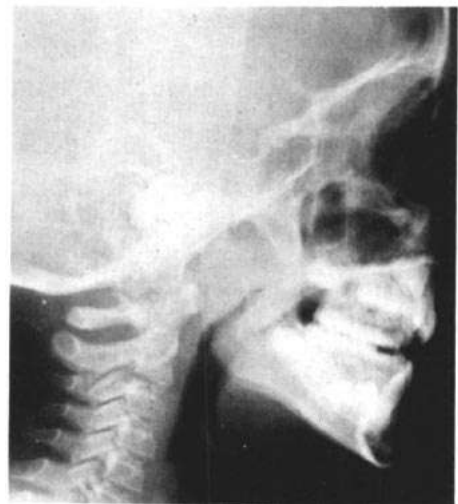

Fig. 2 Lateral cephalometric roentgenogram revealing a large mass of adenoid tissue in the nasopharyngeal area with its anterior aspect apparently obstructing a large part of the posterior nasal choanae.

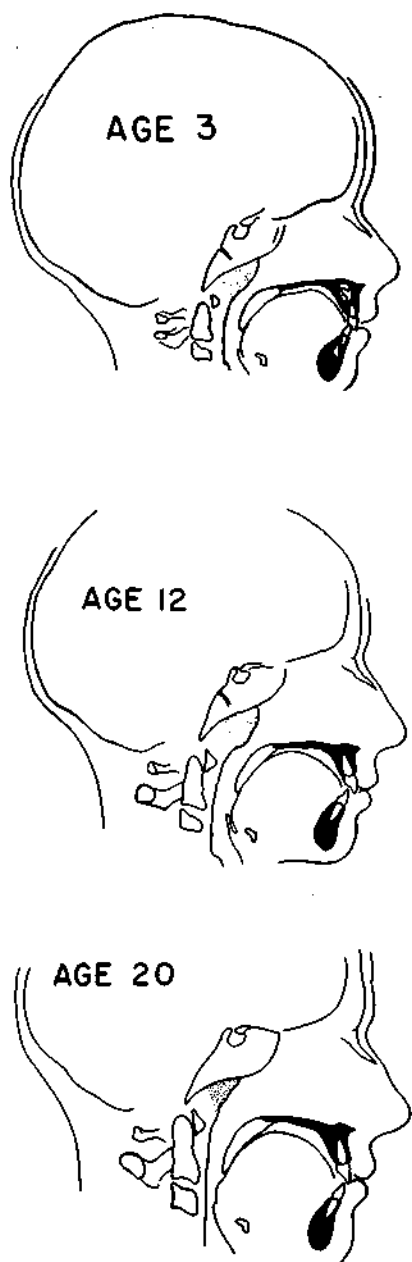


Fig. 3 Tracings of longitudinal cephalometric radiographs at three different age levels. Adenoid tissue (stippled area) was found to have increased to major mass at approximately 12 years of age. Subsequently atrophy of this tissue was noted and by age 20, little if any adenoid tissue is evident.

ation of the relative "closeness" of the adenoid tissue to its surrounding structures would be an important determinant of the probable inadequacy of the nasal-nasopharyngeal airway channel.

Significance can also be found in the 1954 paper in that it was pointed out that there could be differential development in the size of the adenoid tissue and in the size of the surrounding nasopharyngeal cavity. It must be acknowledged that the classic growth curve described by Scammon⁵ for lymphoid growth might not apply to adenoid and tonsillar tissues. Pruzansky⁶ has noted considerable variation in the dimension of adenoid tissue from age to age and speculated that its size at any specific age might be related to individual response to stress. However, in evaluating the changing dimension of adenoid tissue on serial cephalometric roentgenograms, it seems that adenoid tissue does exhibit a developmental cycle superimposed upon which may be the hypertrophic reactions related to the stresses of nasorespiratory infections and allergies. Adenoid tissue was observed to become evident by six months to one year of life and to be quite abundant, occupying about one half of the nasopharyngeal cavity by two to three years of age. Thereafter it seemed to increase in dimension until its greatest mass was noted. In the longitudinal cephalometric series studied, the peak mass was observed to occur as early as nine to ten years of age and as late as fourteen to fifteen years. Thereafter, the adenoid mass seemed to gradually diminish and the nasopharyngeal airway space greatly increased (Fig. 3).

However, whether increase in adenoid mass is solely a reflection of influences exerted by infectious or allergic agents, or does truly manifest

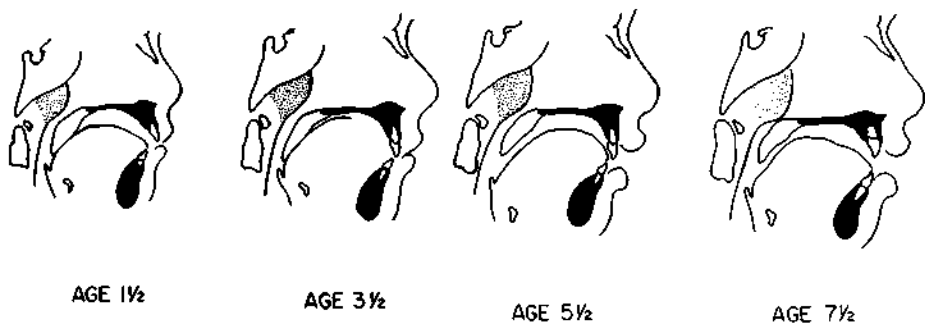


Fig. 4 Tracings of the longitudinal cephalometric radiographs from early age until seven and one-half years of age. It can be noted that there is an imbalance in adenoid tissue development and vertical growth of the nasomaxillary complex. The adenoid tissue now approximates the nasal aspect of the soft palate and a mouthbreathing habit has developed.

a pattern of growth, it must be acknowledged that through radiographic observation adenoid tissue frequently exhibits a rapid increase in size in young children. Often large adenoid masses may be observed during the prepubertal stages of development. During these same stages of development the nasomaxillary complex is growing well and, with continued drop of the palate away from the cranial base, an adequate nasopharyngeal airway space is usually maintained. However, some times an apparent disruption occurs in the balance between increment in adenoid size and increment in the nasopharyngeal cavity dimension (Fig. 4). Either the adenoid tissue mass increases too dramatically or the nasopharyngeal cavity does not increase sufficiently to accommodate the tissue mass. Then there may be a discontinuance of nasal respiration incident to the reduction or elimination of an adequate nasopharyngeal airway channel and oral respiration may become the mechanism for survival. The necessity of oral respiration creates postural changes; the lips part, the mandible repositions in a downward and forward position away from the soft palate to open an oral-pharyngeal airway channel.

The presence of adenoid tissue, by itself, will not cause the development of a mouthbreathing habit and, as a consequence, facial maldevelopment. The nasopharyngeal lymphatic tissue must occupy a sufficiently significant amount of the nasopharyngeal cavity to make oral respiration a necessity. Of particular importance, adenoid tissue may reach this critical dimension prior to or during the time of the prepubertal growth spurt when the jaws are growing at a comparatively rapid rate. With the necessity for mouthbreathing, with the depression of the mandible and the forward posture of the tongue to maintain an open oropharyngeal airway passage, more vertical facial growth may follow. It is conjectured that with the opening of the mandibular jaw to facilitate mouthbreathing, continued eruption of the posterior teeth could be instrumental in increasing anterior lower facial height and increasing the potential for an anterior open bite. Additionally, clinical examination of a significant number of cephalometric headplates taken on youngsters with enlarged adenoid tissue has led to the impression that alteration of the skeletal architecture of the maxillary and mandibular jaws can also occur incident to the mouth-

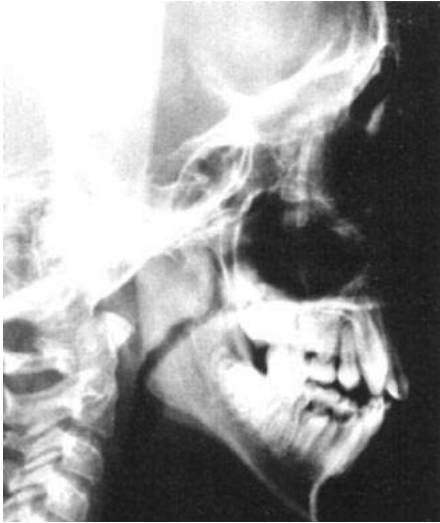

Fig. 5 Cephalometric roentgenogram of an individual with a large amount of adenoid tissue within the nasopharyngeal area. The posterior aspect of the hard palate seems to deviate in a downward direction relative to the anterior cranial base.

breathing process. In examining the nasomaxillary complex, a clinical impression was frequently attained that the hard palate tends to tip down in the posterior region, away from the cranial base, to a greater extent in the mouthbreathers (Fig. 5). Since this impression might result from an optical illusion related to posturing of the whole head in an upward and forward direction away from the cervical column, a study was undertaken to see if this clinical observation could be substantiated.⁷

Thirty-three youngsters with enlarged adenoids were compared with a comparable sample of youngsters with minimal adenoid mass. When the inclination of the palatal plane was measured relative to the SN plane, it was found to deviate significantly less, progressing from the posterior nasal spine to the anterior nasal spine in the mouthbreathing group. In another study, conducted by Adamidis,⁸ subjects with excessive

adenoid masses showed a posterior vertical height of the nasomaxillary complex that was significantly greater than was found in the control subjects. The combination of these findings, as well as clinical observations, indicates that in mouthbreathers the hard palate, as it progresses posteriorly, shows a greater downward deviation relative to the anterior cranial base. One can readily hypothesize that the downward deviation of the posterior aspect of the nasomaxillary complex could be partially responsible for the rapid increase in lower anterior facial height. As in other studies, the mandibular plane was also found to be steeper, diverging more as it progressed from the gonial region to the symphysis, but additionally, by clinical observation it seemed that there was a greater divergence of the lower border of the mandible relative to the ramus, almost an increased curvature or notching anterior to the gonial region⁹ which could also add to the comparatively greater anterior lower facial height.

Additionally, a strong clinical impression was noted that excessive nasopharyngeal blockage might have some effect on the extent of nasomaxillary growth itself. Clinically, many cases were observed to have some degree of maxillary retrusion coincidental to a mouthbreathing habit.⁹ Of course, the question arises as to which comes first, the chicken or the egg. Is the mouthbreathing habit the result of inadequate development of the nasomaxillary-nasopharyngeal complex or vice versa?

Some insight might come from a report by Freng and Kvam¹⁰ who studied youngsters with congenital choanal atresia of the posterior nares on a comparative basis with a control group devoid of malformations in the head or neck region. Of par-

ticular importance to the present discussion, eleven adult subjects of the total sample had complete posterior choanal atresia which had not been operated on during the growing periods and, as a consequence, had no facility for nasal respiration from birth to maturity. In these cases a shorter and retruded maxilla was demonstrated. Concomitantly, there was a tendency toward retrognathism with a steeper mandibular plane incident to a posterior rotation of the mandible. They hypothesize that muscular pull induced by the mouth-breathing process may be the cause of the reduced maxillary dimensions. It might further be surmised that one of the factors relative to a potential for achieving optimal development of the nasomaxillary complex seems to revolve around the ability of sustaining nasal respiration.

THE NASAL CAVITIES:

NASAL TURBINATES AND GROWTH

Acknowledging that the growth of the nasomaxillary complex may, in part, be related to a functional response to the nasorespiratory inflow makes it incumbent upon the orthodontist to look into all of the respiratory spaces when evaluating the possibility of nasal or oral respiration and their relationships to dentofacial morphology. Within the bony nasal cavities themselves, hypertrophied turbinates may be responsible for severely limiting nasal airflow. Frontal cephalometric roentgenographs should be examined not only for the width of the nasal cavities, but also for the size and shape of the nasal septum, for the size and degree of hypertrophy of the bony nasal turbinates located on the lateral walls of the nasal cavities, and the apparent amount of open airway space within the nasal cavities (Fig. 6). The bony turbinates are lined with res-

piratory mucosa which can become chronically swollen incident to inflammation and allergic stresses and project into the normal airstream to the extent that they may obstruct the nasal air passageways. The turbinates, particularly the inferior turbinates, may be observed to approximate or nearly approximate the nasal septum to such a degree as to produce a mechanical blockage to nasal airflow.

Upon examination of the frontal headplate, very little black area may be visible within the nasal cavities which would radiographically represent airway space (Fig. 7). This, of course, is a subjective evaluation. On a lateral headplate greatly enlarged inferior nasal turbinates may sometimes be observed, projecting posteriorly to varying degrees. They may be observed to seemingly approximate the anterior and inferior aspects of adenoid tissue obstructing nasal airflow (Fig. 8). This, too, is a subjective evaluation, but if other indications lead to a conclusion of pos-

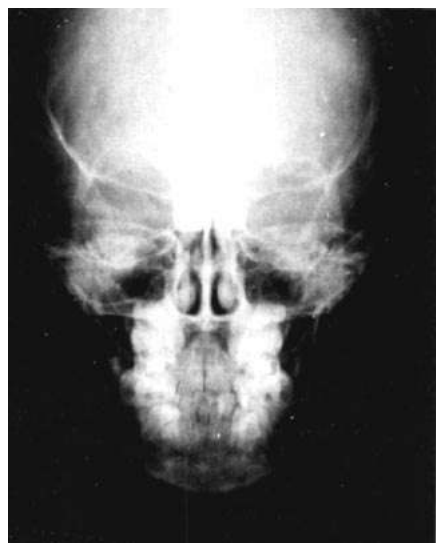

Fig. 6 Frontal cephalometric roentgenogram revealing a clear nasal cavity with a straight nasal septum and considerable airway space (dark area).

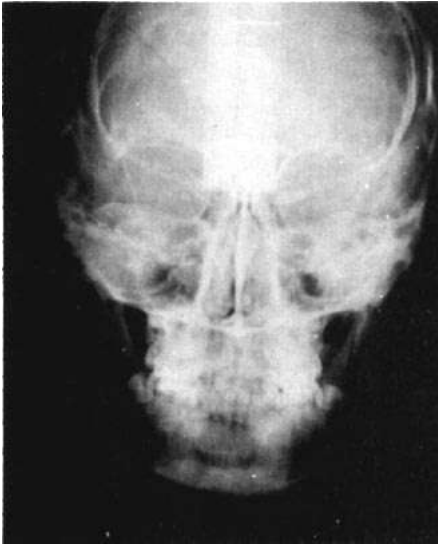

Fig. 7 Frontal cephalometric roentgenogram of an individual with a narrow nasal cavity and enlarged turbinates. Reduced airway space is evident when compared with Figure 6.

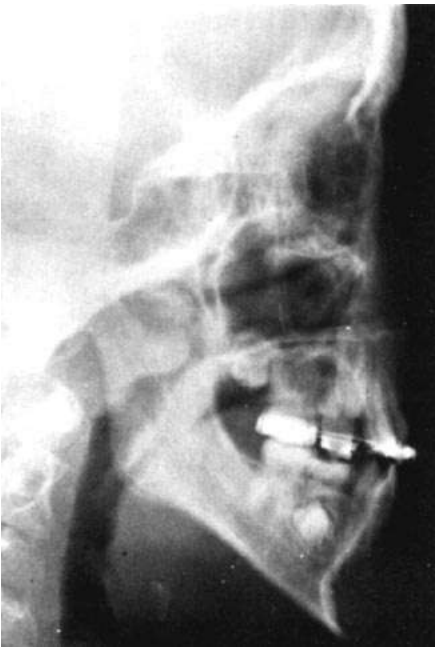

Fig. 8 Lateral cephalometric roentgenogram revealing enlargement of the inferior nasal turbinate which seems to be projecting beyond the area of PTM and possibly contacting adenoid tissue.

sible inadequacy in nasal respiratory processes, then alleviation of the problem should be sought to avoid ill effects in the development of the occlusion and in facial morphology.

To date, the literature reveals little information relative to the growth of the bony nasal turbinates as distinct anatomical entities. Reference to the fact that allergic reactions and chronic nasorespiratory infections can cause increases in the dimensions of the soft-tissue covering is what is frequently noted in the literature. Not only is little known concerning the growth of the turbinates, but additionally not much is known about the effect of turbinate enlargement on maxillary growth per se. It may be hypothesized that a viable nasal respiratory system may be necessary for ideal development of the nasomaxillary complex and the mandibular jaw. It has been demonstrated that intranasal obstructions can minimize or preclude nasal respiration and can affect mandibular development. Woodside and Linder-Aronson¹¹ found, with increment in age, a progressively greater lower anterior facial height in individuals with nasal obstruction when compared with individuals capable of nasorespiratory activity. Problems in mandibular growth, similar to those of mouth-breathers, incident to enlarged adenoids have been noted. Clinically, nasal obstruction of such dimension as to prevent nasal respiration also seems to have some influence on the maxillary architecture as well as the growth of the nasomaxillary complex. Clinically, there frequently seems to be some degree of maxillary retrusion, some degree of anticlockwise rotation of the palate, and some degree of reduction in maxillary width when nasal respiration is not possible. A study has been undertaken to evaluate this possibility.¹²

Of course, one must consider "form" and "function" to be inter-related and that one might possibly affect the other, dependent on the stage of development. Certain hereditary patterns, of necessity, may be more prone to mouthbreathing than other patterns and vice versa be more subject to adverse directions of development incident to the mouthbreathing process. In the instance of a genetically predisposed individual for an unfavorable skeletal-facial morphology, particularly for excessive vertical facial growth, mouthbreathing may be the precipitative factor or the additive factor in the development of an undesirable malocclusion. There must also be critical stages in growth and development when greater influences of adverse function may be exerted relative to the amount and direction of skeletal facial growth. Logically, it would seem that these would be during the earlier stages of development; of particular importance to orthodontics it would seem to be around the prepubertal timing of growth during the period of transitional dentition. If growth can be adversely affected, correction of possible unfavorable influences should be undertaken during or before active growth periods and not subsequent to those periods. Once the die is cast, it may be difficult to alter.

ORTHOPEDIC CORRECTION

To date, orthodontists have had considerable difficulty in the treatment of inadequately developed maxillae leading to midface retrusion as well as maxillary skeletal constriction. Many times the orthodontist waited until adulthood and resorted to surgical corrective procedures such as maxillary surgical advancement or mandibular surgical resection and repositioning. If, as indicated by

the aforementioned studies, oral respiration may be affecting maxillary as well as mandibular growth and development, then corrective procedures should be instituted which may not only alleviate the causative problem, mouthbreathing, but may concomitantly enhance growth and development in the proper direction and adequate amount. In line with these observations, it would seem desirable to not only correct the skeletal-dental discrepancies, but also to create a greater facility for nasal respiration especially during the early growing years, the time of rapid and optimal midfacial growth.

The first of orthopedic-orthodontic approaches that comes to mind to enhance nasal respiration is the procedure of rapid midpalatal suture expansion. It has been demonstrated that this will separate the midpalatal suture and concomitantly, there is histologic evidence of new bone deposition in the suture area.^{13,14} There is testimony of an upward and outward rotation of the two maxillae with the separation in the midpalatal suture. Of particular importance to the present discussion, an increase in the width of the nasal cavity was concomitantly achieved and this increase generally maintained itself with small decreases if a sufficient period of stabilization and retention were undertaken. Whereas a great tendency for reduction in dental arch width was noted years after rapid palatal expansion,¹⁶ the same was not necessarily noted for nasal cavity width. Thus, it would seem that this procedure could create a greater volume of air space within the nasal cavities. There is some information which would lend credence to this possibility. Hershey et al.¹⁷ indicated through their study that rapid palatal expansion is not only effective in increasing the width of the nasal cavity,

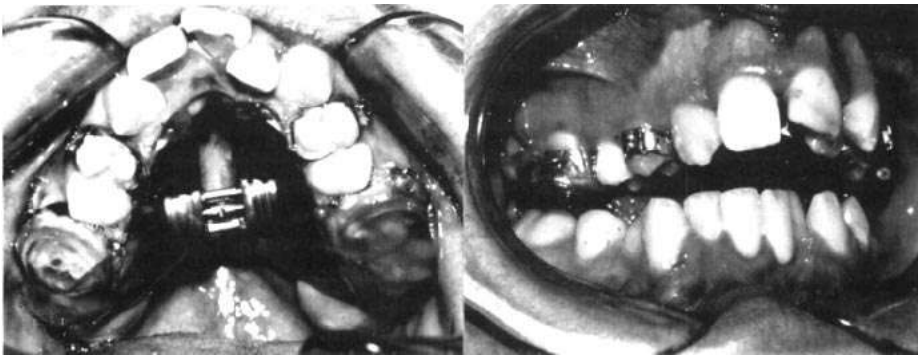


Fig. 9 Occlusal view (left), lateral view (right) of a rapid palatal expander with the addition of an occlusal bite block in the re-

gion of the molars. As noted, upon mandibular closure, depression action can be placed on the mandibular posterior teeth.

but also instrumental in reducing the resistance to nasal airflow. In expanded cases there was a general reduction in the nasal resistance to airflow associated with mouthbreathers to levels which were more compatible with the nasal mode of respiration. This reduction in resistance to airflow was found to be stable through the three-month period of expansion retention. Although long-term studies relative to improvement in nasal airflow subsequent to midpalatal suture expansion are not available, from all indications this orthopedic procedure might be an aid, within limits, in improving obstructed nasal airway passages. On the basis of these observations we have tended to recommend expansion of the midpalatal suture in young children with nasal constriction, enlarged turbinates, and a mouth-breathing problem. Occasionally this procedure has been recommended even in the absence of an evident crossbite, in efforts to facilitate nasal respiration and enhance the possibility of acceptable dentofacial development. One might say this is an unreasonable and even an undesirable procedure since buccal bites might occur. However, some return of dental width can be anticipated

which should obviate some of the problem and, furthermore, continued mandibular growth might bring a wider part of the lower arch forward, relative to the maxillary arch, as maxillary growth slows down and this too might aid in achieving a better occlusion in width.

Today in many instances where opening the midpalatal suture is indicated, an occlusal bite block will frequently be used in conjunction with and as part of the rapid expansion appliance (Fig. 9). Several advantages seem to accrue from the conjunctive use of occlusal bite blocks. With a better grasp and overlay of the crowns there might be a reduction in the molar tipping action than has been previously noted (Fig. 10). Perhaps this results from a greater facility to direct forces onto the nasomaxillary complex via the root structure itself. Furthermore, the occlusal bite block is deemed to be almost necessary when adverse anatomic relationships such as excessive vertical dimension of the face are an important consideration. Reference is particularly made to those cases in which facial growth, notably lower facial growth, is predominantly in a downward direction indicating a possible open-bite tendency, a direction in

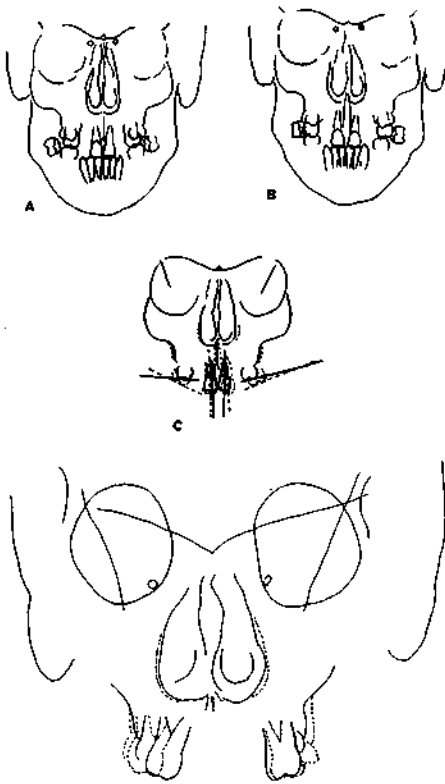


Fig. 10 Above, tracings of frontal cephalograms on the same patient. A) before rapid palatal expansion; B) after palatal expansion; C) superimposed tracing indicating the extent of molar tipping coincidental with the orthopedic expansion. Below, superimposed frontal cephalometric tracings of the same individual before and after rapid palatal expansion with the conjunctive use of an occlusal bite block. Less molar tipping seems possible with the conjunctive use of the occlusal bite block onlay.

which the mandible has been observed to develop in individuals with mouthbreathing problems.

Of particular importance for these children is the prevention of supra-eruption of molar teeth with the ensuing downward and backward repositioning of the mandibular jaw. The posterior occlusal bite block is fabricated to cover the occlusal surfaces of the maxillary posterior teeth and is designed to exceed the freeway space by a considerable dimen-

sion. Its action is directed to the mandibular molars in an effort to directly depress or at least prevent eruption of the mandibular molars. A study was undertaken at the Eastman Dental Center, utilizing longitudinal 45 degree obliques to evaluate the effect of posterior occlusal bite blocks, although not necessarily in conjunction with midpalatal expanders.¹⁸ Several cases were followed and some of the observations are pertinent to the present discussion. There was a difference in response to the occlusal posterior bite-block therapy in the adult in comparison with the growing child. In the adult, intrusion of the opposing posterior teeth seemed to be the adaptive response to the increased vertical dimension. It can be hypothesized that exceeding the freeway space caused a stretching of the masticatory muscles and after a period of

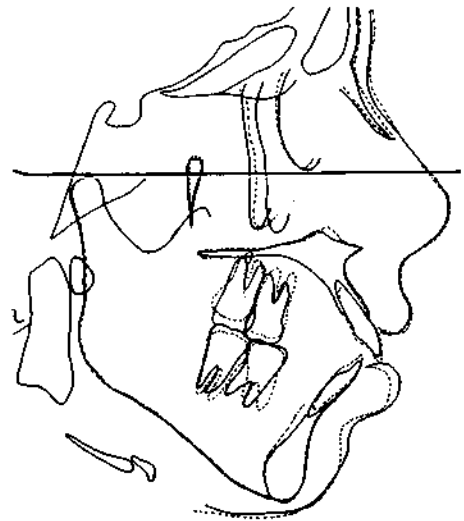


Fig. 11 Superimposed tracings of lateral cephalometric roentgenograms indicating effects of posterior bite block therapy of 21 months (dashed line) on vertical dimension and posterior teeth. This and all other lateral tracings are superposed on the maximum number of structures of the anterior cranial base and registered on sella turcica. (Taken from R. Buck, Eastman Dental Center, 1979).

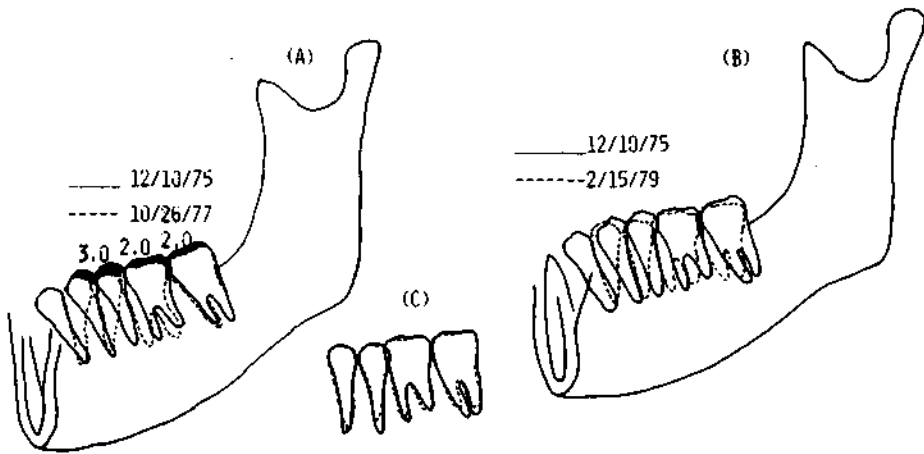


Fig. 12 Superimposed tracings of the right oblique cephalometric roentgenograms of the same individual depicted in Figure 11 indicating extent of intrusion, extent of rebound, and degree of apical resorption incident to bite block therapy. To be noted is the fact that molar teeth were uprighted and maintained this inclination and did not open the vertical dimension. (Illustration taken from Buck.)

time these muscles forced an intrusion of the posterior teeth. In actuality, posterior open bites were created as the cuspids and anterior teeth achieved occlusal contact while the posterior teeth were depressed; there was no observable decrease in the anterior facial height (Fig. 11). The bite block appeared particularly helpful in uprighting tipped molars to good axial inclinations. Subsequent to the removal of the posterior bite block, there was a rebound effect with eruption of the depressed teeth, but under appliance control it was possible to keep teeth upright and to prevent opening of the bite (Fig. 12). Unfortunately, occasional apical root resorption was observed but this was limited to the areas of minimal periodontal fiber distribution, the apices of the teeth. In growing individuals intrusion of the posterior teeth was not observed; the bite block served to prevent the eruption of teeth in the buccal segments. It would seem that the addition of the occlusal onlay to the palatal expanders in children would be par-

ticularly desirable in vertical developmental patterns where extrusion of the lower molars would serve to therapeutic disadvantage. It would also be particularly helpful in the situation where erupted or erupting molars are mesially inclined and continual eruption would serve disadvantageously to increase anterior vertical facial dimension. The occlusal onlay, serving as a biteblock, should be most helpful in maintaining vertical dimension and preventing increase in the height of the posterior dentoalveolar regions.

Where orthopedic expansion of the nasomaxillary complex has been accomplished, rather than utilizing acrylic to stabilize the expansion mechanism and to permit an appliance to stay in place for a minimum period of three months, a special retainer is recommended. Studies^{18,19,20} seem to indicate that expansion of the nasal cavities is well-maintained while one can usually anticipate considerable reduction in the width of the dental arch. One can surmise, as has apparently been substantiated

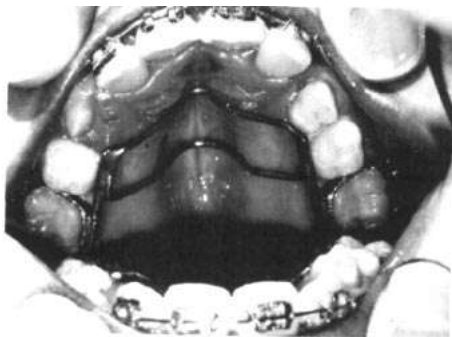

Fig. 13 Photograph of the special retentive mechanism utilized subsequent to rapid palatal expansion to stabilize the maxillary jaws and buccal dentition.

through experiments conducted by Harvold,²¹ that the tongue itself can be instrumental in maintaining expanded arches if it relates well to the dentition or permits some constriction if it does not adapt to, or is too small for, the expanded arches. The tongue may still remain in a low oral posture because of the position and dimension of the expansion appliance. It would seem desirable to make it as facile as possible for the tongue to reposition as soon as possible into the maxillary region, lingual to the maxillary buccal dentoalveolar processes. Thus, the fabrication and placement of an appliance that will not only stabilize the maxillary jaws but will also facilitate tongue repositioning into the palatal region is recommended following expansion (Fig. 13). Hopefully, it will help minimize reduction of what has been achieved in dental arch width.

Maxillary deficiency is a problem not only in width, but also in height and depth. Stimulation in maxillary development may not only reside in opening the midpalatal suture, but also may be necessary to enhance development in maxillary vertical and anteroposterior dimensions. Skeletal midface deficiency is a problem that has not been readily amenable to or-

thodontic correction since, until recently, it was not deemed possible to improve this skeletal imbalance by moving the nasomaxillary complex anteriorly. As a consequence, we frequently sought to improve the skeletal deviation of maxillary retrusion by concentrating our efforts on the mandible. Clinically, when Class III elastics failed, we concentrated on the chin cap hoping to restrict mandibular growth as believed by Graber.²² At the Eastman Dental Center we found the chin cap to be most effective in cases of mandibular overclosure leading to an anterior crossbite and giving the appearance of mandibular prognathism. A study was undertaken²³ which indicated that correction was largely the result of repositioning the mandible in a downward and backward posture permitting molar eruption and a concomitant increase in lower facial vertical dimension. In many of these cases skeletal maxillary retrusion was not necessarily the problem; it was excessive forward and upward positioning of the chin. A need was still present to stimulate forward maxillary development. It has been shown in animal experimentation^{24,25} that anteriorly directed extraoral forces can reposition the maxillary complex anteriorly by influencing sutural opening and producing compensatory deposition and resorption of bone at sutural margins. If this can be accomplished in the monkey, then logically, with adaptation in appliance construction and force adaptation, favorable results should be achieved in patients with skeletal maxillary retrusion. We were frustrated in our attempts to stimulate maxillary forward development until we became cognizant of an appliance advocated by Delaire²⁶ and clinically popularized by Verdon,²⁷ the orthopedic face mask. Delaire and Verdon advocate the utilization

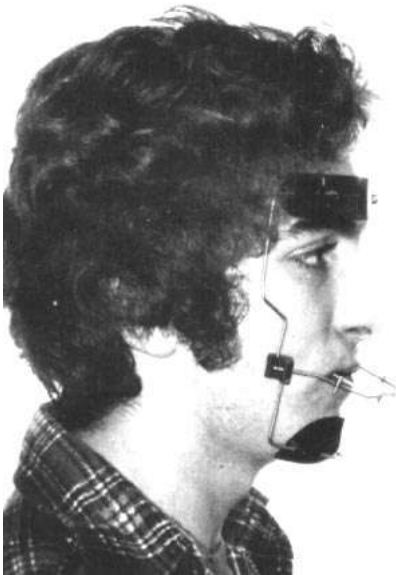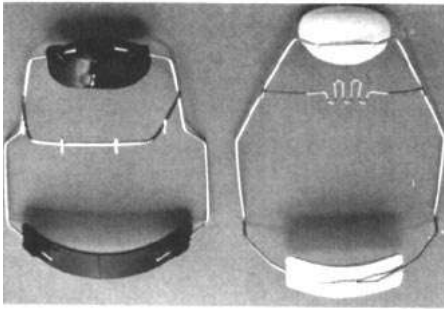


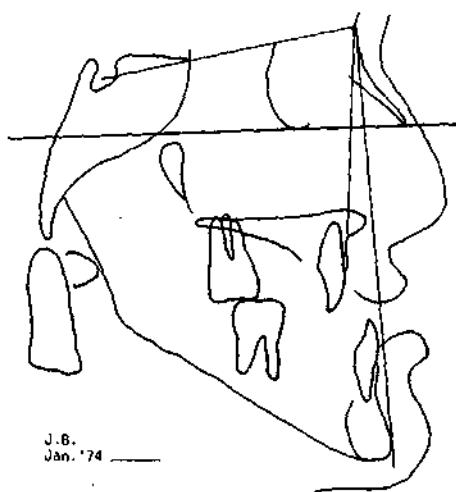
Fig. 14 Above, two different face masks: to the left a face mask produced by Great Lakes Laboratories, Buffalo, N.Y.; to the right the orthopedic face mask produced by Rocky Mountain France, clinically popularized by Verdon. Below, a young individual wearing a face mask with elastics attached to produce forward movement of the maxillary region. Records on this individual are presented in Figures 15 and 20.

of the face mask in patients with maxillary insufficiency and in patients with open bites. Basically, the face mask has a forehead rest, a chin cap for anchorage, and an intermediate portion for the attachment of elastics to produce a forward movement of the maxillary complex (Fig. 14). A heavy orthopedic elastic force is used, approximating one and one-

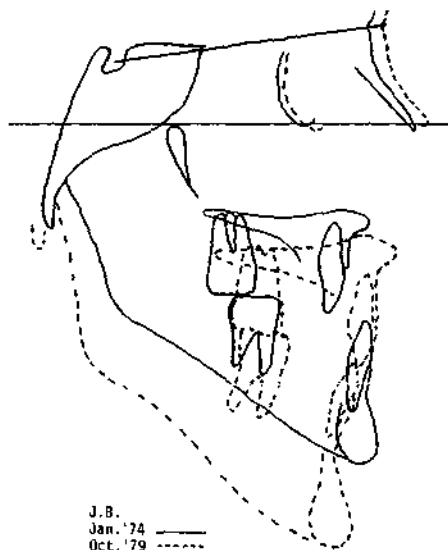
half to two pounds, pulling from the distal of the lateral incisors on each side of the maxillary arch. The elastic pull is in a downward and forward direction and is attached to the face mask at or below the level of the occlusal plane. Delaire and Verdon contend, and our clinical experience confirms, that if the pull comes from the distal part of the maxillary arch from the region of the molars, the occlusal plane will be tipped down in the posterior region and the bite will open; even a horizontally directed force will tend to open the bite. They further maintain that treatment should be initiated at early age levels which will permit movement of the maxillary complex itself as well as the dentition.

Clinically, both in the orthodontic department at the Eastman Dental Center and in private practice, much success has been observed in the use of the face mask in cases with maxillary retrusion. In a pilot study conducted at the Center²⁸ ten subjects who had undergone face mask therapy in conjunction with more conventional orthodontic therapy were evaluated utilizing the gamut of conventional orthodontic records. The cephalometric roentgenograms used for analysis were those obtained prior to the initiation of orthodontic therapy; those taken at the time of initiation of face mask therapy and finally, those secured at the time of completion or near completion of face mask therapy.

Effects of such therapy on the maxillary complex as represented by point A and on mandibular position were evaluated. General superimpositioning permitted general evaluation and analysis of the influences exerted and results achieved. It was clear that skeletal and maxillary dental arch advancement could be achieved through face mask therapy dependent on age.



J.B.
Jan. '74



J.B.
Jan. '74 ———
Oct. '79 - - - - -

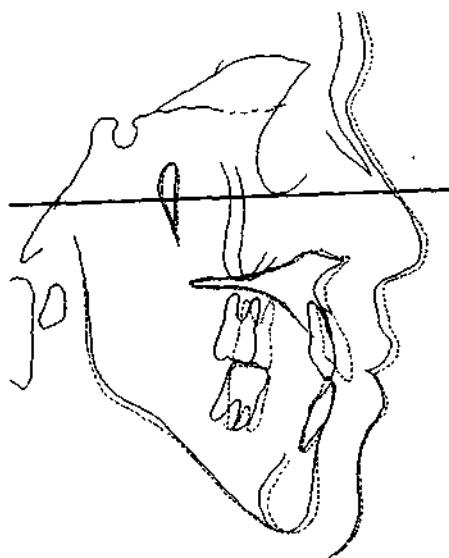
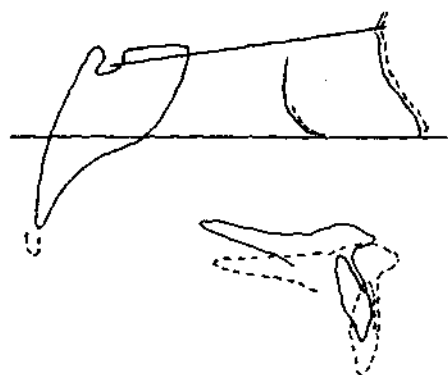


Fig. 16 Superimposed tracings where face mask therapy was instituted subsequent to the pubertal peak in the growth curve. Anteroposterior development of the maxillary region is noted. This subject was also undergoing occlusal bite block therapy and orthodontic therapy because of the vertical pattern of growth and open-bite tendency.

The greatest amount of skeletal anteroposterior maxillary development was found in the younger patients, those who by the wrist plate were determined not to have reached their peak of pubertal growth (Fig. 15). Anteroposterior development of the skeletal maxillary complex was observed in subjects past the pubertal peak of the growth curve, but this seemed to be of a lesser amount and more slowly achieved (Fig. 16). In the



Fig. 15 Tracing of the initial cephalometric radiograph and superimposed tracings of cephalometric radiographs taken before and after face mask therapy on the individual presented in Figure 14. Top, tracing of initial lateral cephalometric radiograph. Center, changes in the facial complex and jaw relationships incident to early orthodontic treatment followed by an intensive period of face mask therapy. Below, superimposed tracings to indicate the extent of maxillary advancement incident to face mask therapy.

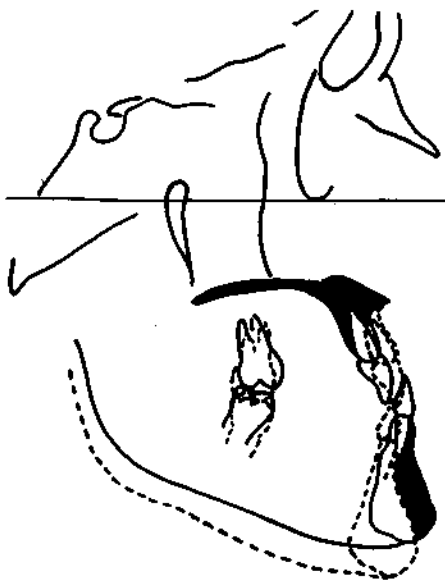


Fig. 17 Superimposed tracings of lateral cephalometric roentgenograms taken on an adult orthodontically treated with a face mask as well as a more usual orthodontic appliance. Approximately two years of face mask therapy has helped to advance the maxillary dentoalveolar complex and has improved jaw relationships despite the completion of craniofacial growth.

late adolescent level and at the adult level, results seemed to be more relegated to the maxillary dentoalveolar process, still favorable although limited (Fig. 17). With the utilization of the face mask the anterior aspect of the maxillary complex was observed to move in a downward and forward direction and did not rotate in a counter-clockwise direction as has been observed in animal studies.

The force, as suggested by Delaire and Verdon, was initiated from the anterior maxillary region with hooks placed distal to the maxillary lateral incisors. In practice, some individual and apparently helpful modifications have been introduced prior to the initiation of face mask therapy. It was found desirable to attain considerable labial root torque in the upper incisal region before face mask use (Fig. 18). This procedure was introduced to minimize stripping of the labial alveolar crests and reduce elongation of the incisors along their long axes. A welcome bonus was an appar-

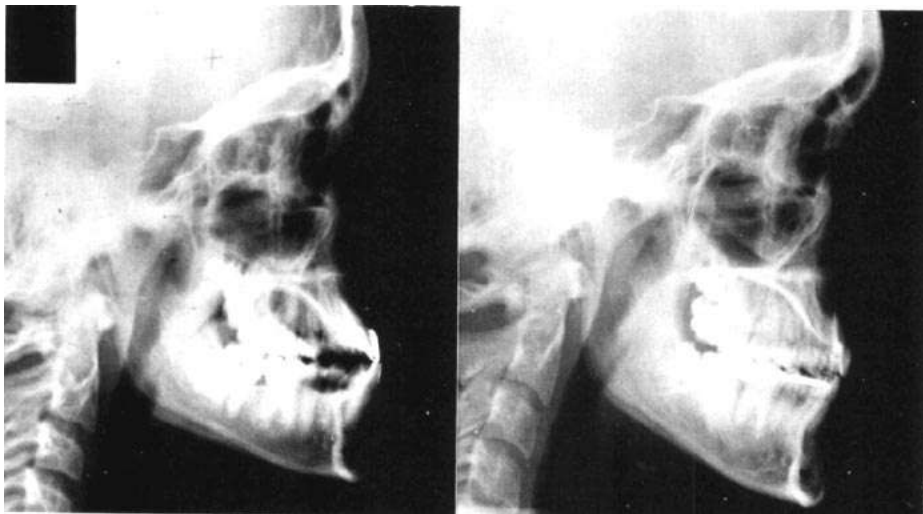


Fig. 18 Lateral cephalometric roentgenograms taken on the same individual, before (left) and after (right) face mask therapy. One of the maxillary central incisors had been endodontically treated. The later cephalograms indicate the amount of anterior labial root torque that had been achieved which seemed helpful to nasomaxillary advancement. Note, there have been extractions of mandibular premolars and good dentofacial relationships despite continued mandibular growth.

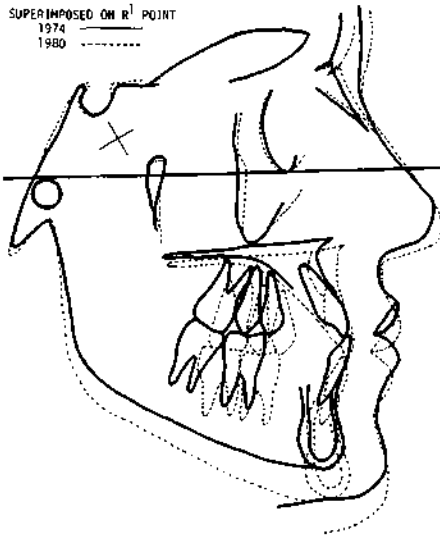


Fig. 19 Superimposed tracings to indicate the long-term effect of face mask therapy on the direction of mandibular development. Earlier superposed tracings of the patient are depicted in Figure 16. Considerable vertical mandibular development can be noted.

ently greater bodily effect on anterior maxillary movement. This, of course, is contrary to all present-day teaching relative to the proper labial-lingual root or torque inclination of the maxillary incisor teeth, but served well for achieving anterior maxillary movement.

Labial root torque of the incisors seemed to promote development of point A. Frequently the root tip was brought close to the cortical plate as observed on a cephalometric head-plate. There was some apical root resorption to be noted, but this was primarily in older patients and was not severe. The maxillary molars were observed to come forward as well as the incisors and, strangely in most cases, the anterior nasal spine became more clearly visible on the cephalometric roentgenogram and measured out to a longer dimension after face mask therapy. To date, after maxillary development has been achieved

a strong relapse tendency has not been observed. With labial root torque whose maintenance is recommended, development of point A seems to be retained and increase in overbite is achieved which would resist relapse of the maxillary retrusion. At this time, it should be pointed out that the face mask can be used in conjunction with a maxillary edgewise Hawley retainer when an appreciable amount of mandibular growth is still anticipated.

The focus of face mask therapy is on the maxillary region, but in addition to the forehead rest for anchorage, there is a chin cup rest for anchorage. Since the mandible is a moving and, many times, a growing jaw, it is logical to assume the face mask has some effect on the lower jaw itself. The effect was noticed to be variable, but general trends are worthy of note and probably helpful in the observed improvement in facial appearance. When facial growth is still present, the mandible seemed to usually develop more vertically than horizontally. The chin was observed to progress in a more vertical direction with continued growth, while the lower border seemed to generally maintain a parallel relationship. Some, though small, rotation of the mandible was noted since there was but little change in the mandibular plane angle. It seemed as though the face mask was helpful in posturing the mandible in a more downward and somewhat backward direction during the process of midfacial advancement (Figs. 15 and 19).

Clinically, both at the Eastman Dental Center and in private practice, face mask therapy has been quite impressive in cases with some mid-face retrusion. In some cleft palate cases it seems to have obviated the need for maxillary surgical advancement (Fig. 20). This orthopedic ap-




Fig. 20 Photographs and profile tracings of an individual (Fig. 15) with a repaired cleft of the lip and palate who had undergone orthodontic treatment including face mask therapy. Considerable improvement in early midface retrusion is clearly evident.

pliance, the maxillary palatal developer, and conjunctive use of bite blocks, where indicated, seem to orthopedically offer the ability to widen and to increase the horizontal and vertical dimensions of the nasomaxillary area. To date, the results achieved seem to maintain themselves in that rapid relapse is not noted. However, substantiation as to whether these procedures permit increased na-

sal respiration and improved nasomaxillary development must await long-term observation and further investigation. Improvements in occlusion and dentofacial configuration have been noted as a very beneficial and desirable bonus in these appliance approaches to maxillary development. Despite the fact that long-term substantiation is still needed, it must be acknowledged that mouthbreathing seems to be a problem in dentofacial development. Anything that we as orthodontists can undertake to improve and permit nasal respiration would seem to be desirable and helpful and should be attempted.

Eastman Dental Center
Rochester, N.Y. 14620

REFERENCES

1. Subtelny, J. D.: The significance of adenoid tissue in orthodontia. *Angle Orthodont.*, 24:59-69, 1954.
2. Emslie, R. D., Massler, M., and Zwemer, J. D.: Mouthbreathing: etiology and effects. *J. Am. Dent. Assoc.* 44:506-521, 1952.
3. Koski, K., and Lahdemaki, P.: Adaptation of the mandible in children with adenoids. *Am. J. Orthodont.* 68:660-665, 1975.
4. Linder-Aronson, S., Backstrom, A.: A comparison between mouth and nose breathers with respect to occlusion and facial dimensions. *Odont. Revy.* 11:343-376, 1960.
5. Scammon, R. E., Harris, J. A., Jackson, C. M., et al.: *The Measurement of Man.* University of Minnesota Press, Minneapolis, 1930.
6. Pruzansky, S.: Roentgencephalometric studies of tonsils and adenoids in normal and pathologic states. *Annals of Otol., Rhinol., Laryngol.* 48: Suppl 19, No. 2, Part 2, 55-62, 1975.
7. Abidari, P. A.: Adaptation of the hard palate in children with large adenoids. Unpublished Senior Certificate Research Presentation, Department of Orthodontics, Eastman Dental Center, Rochester, New York, 1978.
8. Adamidis, J.: Personal communication, unpublished research study. Department of Preventive Dentistry, University of Athens, Athens, Greece, 1979.
9. Cancelli, F.: The effects of adenoid tissue on the morphology of the mandible and the palate. Unpublished Senior Cer-

- tificate Research Presentation, Department of Orthodontics, Eastman Dental Center, Rochester, New York, 1980.
10. Freng, A., and Kvam, E.: Facial sagittal growth following partial basal resection of the nasal septum: a retrospective study in man. *Europ. J. Orthodont.* 1, No. 2:89-96, 1979.
 11. Woodside, D. G., and Linder-Aronson, S.: The channelization of upper and lower anterior face height compared to population standard in males between ages six to twenty years. *Europ. J. Orthodont.* 1:25-40, 1979.
 12. Etengöff, R.: Nasal airway obstruction and its effects on maxillary growth. Unpublished Senior Certificate Research Presentation, Department of Orthodontics, Eastman Dental Center, Rochester, New York, 1980.
 13. Brossman, R. E., Bennet, C. G., and Merow, W. W.: Facioskeletal remodeling resulting from rapid palatal expansion in the monkey. *Arch. Oral Biol.*, 18:987-994, 1973.
 14. Cleall, J. F., Bayne, D. I., Posen, J. M., and Subtelny, J. D.: Expansion of the midpalatal suture in the monkey. *Angle Orthodont.* 35:23-35, 1965.
 15. Stambach, H., Bayne, D. I., Cleall, J. F., and Subtelny, J. D.: Facioskeletal and dental changes resulting from rapid maxillary expansion. *Angle Orthodont.* 36:152-164, 1966.
 16. Linder-Aronson, S., and Lindgren, J.: The skeletal and dental effects of rapid maxillary expansion. *Brit. J. Orthodont.* 6:No. 1, 25-29, 1979.
 17. Hershey, H. G., Stewart, B. L., and Warren, D. W.: Changes in nasal airway resistance associated with rapid maxillary expansion. *Am. J. Orthodont.*, 69:274-284, 1976.
 18. Buck, R.: A study of the treatment effects of the posterior occlusal bite block. Unpublished Senior Certificate Research Presentation, Department of Orthodontics, Eastman Dental Center, Rochester, New York, 1979.
 19. Timms, D. J.: Long term follow-up of cases treated by rapid maxillary expansion. *Trans. Europ. Orthodont. Soc.*, 211-215, 1976.
 20. Hoffer, F. L., and Walters, R. D.: Adaptive changes in the face of the Macaca Mulatta monkey following orthopedic opening of the midpalatal suture. *Angle Orthodont.* 45:282-290, 1975.
 21. Harvold, E. P.: *Experiments on Mandibular Morphogenesis; Determinants of Mandibular Form and Growth.* Monograph No. 4, Craniofacial Growth Series, University of Michigan, Ann Arbor, Michigan, 155-178, 1975.
 22. Graber, T. M., Chung, D. D., and Aoba, J. T.: Dentofacial orthopedics versus orthodontics. *J. Am. Dent. Assoc.* 75:1145-1167, 1967.
 23. Bowman, C. J.: Chin cap and reverse headgear therapy. Unpublished Senior Certificate Research Presentation, Department of Orthodontics, Eastman Dental Center, Rochester, New York, 1975.
 24. Delaire, J.: La croissance maxillaire: deductions therapeutiques. *Trans. Europ. Orthodont. Soc.* 81-102, 1971.
 25. Verdon, P., and Salagnac, J. M.: Traitments originaux de quelques cas complexes. Utilisation successive des forces extra-orales (masque orthopedique de Delaire et plaque de Stephenson) et des forces légères (technique de Mollin). *L'Orthodontic Francaise*: 47, tome 2, 802-811, 1977.
 26. Jackson, G. W., Kokich, V. G., and Shapira, P. A.: Experimental and postexperimental response to anteriorly directed extraoral force in young Macaca Nemestrina. *Am. J. Orthodont.* 75:318-333, 1979.
 27. Kambara, T.: Dentofacial changes produced by extraoral forward force in the Macaca Irus. *Am. J. Orthodont.* 71:249-277, 1977.
 28. Fenn, C.: The clinical and cephalometric results of face mask therapy in the dentofacial region. Unpublished Senior Certificate Research Presentation, Department of Orthodontics, Eastman Dental Center, Rochester, New York, 1979.